

XXI. *Contributions to the Minute Anatomy of the Thyroid Gland of the Dog.* By
E. CRESSWELL BABER, *M.B. Lond.* Communicated by Dr. KLEIN, *F.R.S.*

Received December 9, 1875,—Read January 27, 1876.

THE thyroid gland is one of those organs, commonly known by the name of ductless or blood-glands, about which our knowledge is still in a very unsatisfactory condition. The function of this body is quite unknown, and its minute structure is still involved in some obscurity*.

Results of previous Investigations.—The present state of our knowledge of the structure of this organ may be gathered from the writings of HENLE ('Handbuch der systematischen Anatomie des Menschen,' 1866, vol. ii. pp. 535–541), KÖLLIKER ('Handbuch der Gewebelehre,' 5th ed. 1867, pp. 480–482), VERSON (STRICKER'S 'Human and Comparative Histology,' Sydenham Society's translation by H. POWER, vol. i. pp. 370–372), and FREY (Das Mikroskop, 4th ed. 1871, pp. 232 & 283).

According to these authors the thyroid gland consists of numerous vesicles, embedded in, and supported by, a stroma or framework of connective tissue containing blood-vessels, nerves, and lymphatics.

The Stroma.—The stroma is directly continuous with the capsule of connective tissue investing the gland, from which strong trabeculæ pass inwards, dividing the gland into lobes, and from these, again, finer septa originate, which subdivide the lobes into lobules (*Drüsenkörner*, KÖLLIKER). "In this way the thyroid gland of man is divided into primary and secondary segments, the line of division between which is recognizable by slight furrows" (VERSON). The connective tissue lying between the several gland-vesicles is, according to the same author, very sparing in quantity, and sometimes even it is difficult to discover between the walls of contiguous vesicles a few fibres accompanying the capillaries. HENLE finds that the vesicles are partly separated by fine connective-tissue septa, and are partly in direct contact with one another. "The septa," he further says, "are not only relatively, but absolutely greater between the small vesicles than between the larger ones, which gives the appearance as if the connective tissue were compressed or displaced by a distension of the vesicles."

In structure the stroma consists of ordinary connective-tissue fibrils, with fine elastic

* On this point the following remark of HENLE'S is of interest. Referring to the ductless glands, he says (Handbuch d. system. Anat. vol. ii. p. 535):—"Of many of these we believe that we know the ultimate elements and their arrangement. But as long as the function, not only of these elements, but also of the organs themselves, remains an unsolved problem, one cannot but suspect that their anatomical structure contains some hidden secret."

fibres and connective-tissue corpuscles. On the surface it also contains fat-cells (KÖLLIKER).

The Gland-vesicles.—The gland-vesicles (*Drüsenbläschen*, KÖLLIKER) of the thyroid gland are described as closed globular bodies, consisting of a very fine homogeneous membrane (*membrana propria*) lined by a single layer of epithelial cells (KÖLLIKER, HENLE, VERSON). FREY, on the contrary, does not believe in the presence of a *membrana propria*. He thinks that the connective-tissue wall of denser texture, when examined with imperfect methods of preparation, may have deceived earlier observers. Authors differ in their description of the epithelial cells. HENLE describes them as a single layer of flattened cells containing circular nuclei, and resembling a layer of epithelium. According to KÖLLIKER they are polygonal, finely granular, transparent cells, each with a single nucleus. FREY, again, alludes to them as flattened, cylindrical, nucleated cells. Finally, VERSON, in opposition to HENLE, lays stress on the fact that the cells in the fresh condition are always somewhat higher than broad. Accurate measurements of the gland-vesicles and of the epithelial cells are given by the different authors, into a consideration of which it is needless to enter here.

The cavity of the vesicle is described as occupied by a clear viscid fluid (KÖLLIKER and FREY) slightly tinged with yellow, and containing much albumin (KÖLLIKER). HENLE speaks of the contents as clear, and becoming converted by the action of alcohol into a firm, somewhat shrunken coagulum.

These authors all allude to the occurrence of a *colloid* material in the vesicles, which they consider a pathological condition. KÖLLIKER, however, found it in new-born children, and VERSON “at an advanced age.”

The Lymphatics.—FREY, who is the last observer who has worked at these, gives the following account of them, as quoted by HENLE (*loc. cit.*):—The large lymphatics covering the capsule of the thyroid gland take their origin from a rounded network which surrounds the secondary lobules. From these there branch off finer arborescent canals for the primary lobules, to surround them with perfect rings or with arches more or less complete. From these, again, a few finer canals dip down among the individual vesicles and end in blind extremities.” In ‘Das Mikroskop und die mikroskopische Technik,’ 4th edition, 1871, p. 283, FREY describes the lymphatics as quoted above by HENLE, until he arrives at the statement that “a few finer canals not uncommonly dip down among the individual vesicles.” He then stops, and does *not* confirm his statement of their ending in blind extremities.

The object with which the present research was undertaken was a minute investigation of the lymphatics of the thyroid gland of the dog, with a view to rendering more accurate our knowledge of their structure and distribution. In the course of the investigation, however, I found it necessary to study more carefully the vesicular and inter-vesicular tissue, and was then led to observe certain cells in the latter which have not, as far as I am aware, yet been described. I shall therefore treat the subjects of this paper under two headings:—I. The Lymphatics; and II. The Parenchyma.

I. THE LYMPHATICS.

Methods.—The methods of investigation adopted were the following, viz. :—

1. *Injection with Berlin blue.*—The thyroid gland of a freshly killed dog was injected *in situ* with a solution of Berlin blue, by the method of puncture with a subcutaneous syringe. When the gland was sufficiently injected (the naked eye appearances it then presented are described below), it was removed and hardened, either

a. In methylated spirit only, or

b. First in MÜLLER'S fluid, and then in methylated spirit.

When sufficiently hard, portions were embedded and stained and mounted in balsam in the usual way.

2. *Injection with Nitrate of Silver.*—Fresh thyroid gland of the dog was injected in a similar manner with $\frac{1}{8}$ per cent. solution of nitrate of silver in water. The gland was then removed and hardened in alcohol, and portions of it were treated as before. Throughout this research the thyroid glands examined were those of adult dogs only.

Characters and Distribution.—The lymphatics of the thyroid gland, when examined by the above methods, presented the following characters.

1. *Macroscopic Appearances.*—The thyroid gland in the dog, as is well known, consists of two separate portions, situate on either side of the trachea and in front of the vertebral column. On inserting the nozzle of a hypodermic syringe into one of these glands, and injecting Berlin blue solution, the following appearances presented themselves :—

The whole gland swelled up, and a fine network of injected vessels appeared on the surface of the organ, which could be distinctly seen with a hand-lens. At the same time lymphatic vessels became injected running from the gland, and these were distributed in the following manner :—Several branches came off from the lower and inner extremity of the gland. These soon joined to form a single vessel, which, running in a direction obliquely downwards and inwards in front of the trachea, entered a small lymphatic gland situate in the median line over about the sixteenth ring of the trachea. The vessels emerging from the upper part of the thyroid gland, which were larger and more numerous than the preceding, formed a plexus immediately above it; and from this there came off two principal branches, the one running upwards and inwards over the front of the windpipe, the other taking a course outwards and upwards and terminating in a large lymphatic gland situate under the upper part of the sterno-mastoid. This gland became partly injected with the Berlin blue. In size it nearly equalled the thyroid gland itself.

On examining with a hand-lens the surface of a thyroid gland that had been injected in a similar manner with nitrate-of-silver solution, a fine network of lymphatics was also seen, resembling somewhat in shape and distribution those to be afterwards described in the interior of the organ (Plate 47. fig. 3).

2. *Microscopic Appearances.*—Before describing these it will be necessary to say a few words with regard to the general structure of the thyroid gland of the dog, as I

have observed it in specimens prepared by the above-mentioned methods, in order to render the descriptions that are about to follow intelligible.

First, with regard to the *stroma*. In the dog, as above mentioned, the thyroid gland consists of two separate portions. Each of these forms apparently a single lobe, which is divided into lobules, more or less distinctly, by processes of connective tissue passing inwards from the surface of the organ, where they are continuous with the connective-tissue capsule surrounding the gland. These bands of connective tissue run chiefly with the blood-vessels, and gradually diminish in size, till between the individual vesicles it is often impossible to say that there is any stroma present. On the whole the connective-tissue stroma appears very sparing in quantity in the thyroid gland of the dog.

The Vesicles.—Between the different ramifications of the stroma are seen the vesicles with their walls, consisting of a single layer of cells arranged like an epithelium, and usually known as “epithelial cells.” These commonly present a square or wedge-shaped outline, though their shape varies in different preparations and in different parts of the same specimen. They are usually higher than broad (Plate 48. figs. 8, 13); sometimes, however, they present a more or less flattened appearance, probably the effect of the reagents (Plate 47. fig. 1). Under certain circumstances these cells present a more or less triangular outline, of which more hereafter. Their cell-substance is finely granular, and they are each provided with a single spheroidal nucleus. With regard to the existence or not of a *membrana propria* outside the epithelial cells, I am not in a position to make any definite statement. I may, however, draw attention to the following appearance which I have noticed once or twice in these preparations. In a vesicle where the epithelial cells are partly deficient a distinctly marked line, which occupies the curved *inner* aspect of the epithelial layer, is directly continued onwards in the same direction, for a distance of at least two or three cells, beyond the point where the cells cease to be present. This gives an appearance as if there were a distinct membrane lining the inner aspect (or summits) of the epithelial cells, those that are deficient seeming to have become separated from it. This appearance, however, is probably produced by a layer of hardened secretion adhering to the cells. As mentioned by VERNON (*op. cit.* p. 371), in the dog the walls of the vesicles are frequently seen to be inflexed, forming projections into the cavities of the vesicles.

Contents of the Vesicles.—The contents of the vesicles consist, in addition to a small quantity of a pellucid substance sometimes present, of a peculiar material which shrinks away from the walls of the vesicle and forms a solid mass in the centre. In sections stained with picocarminate of ammonia it appears as a finely granular substance of a more or less bright yellow hue, contrasting with the red colour of the walls of the vesicles. In specimens coloured with hæmatoxylin, on the other hand, it presents the appearance of an opaque, grey, or greyish-violet mass, which is generally uniform, but sometimes finely granular, in appearance.

From a careful examination of sections of the thyroid gland prepared by the above

methods, the characters and distribution of the lymphatics within the gland were found to be as follows:—

Traversing the gland, chiefly in a longitudinal direction, and accompanying the larger blood-vessels and septa of connective tissue, are numerous *lymphatic vessels* of considerable size. They not uncommonly surround the arteries which they accompany, as represented in Plate 47. fig. 1, and even completely invaginate them, so as to represent “perivascular lymphatics” (see fig. 5). These vessels are in direct connexion with the network of lymphatics already described on the surface of the organ (see p. 559). They are provided with valves; and their walls are formed by a layer of endothelium, the cells of which are elongated and have a somewhat sinuous outline. Many of these cells appear to be provided with two, or even three, oval-shaped nuclei (see fig. 7). The endothelial markings are well seen in specimens prepared according to method 2, and the nuclei sometimes assume a faint violet tint from the hæmatoxylin.

As represented in figure 7, the nuclei are not uncommonly seen as if lying under the silver line separating two adjacent cells, a part of the nucleus being on one side of the line and part on the other.

Coming off from these vessels, and traversing the gland in all directions, are *numerous lymphatic tubes* of very varied size and shape. The larger ones run principally between groups of vesicles, and are in direct communication with smaller ones which pass between individual gland-vesicles. The latter (the “few finer canals” of FREY), in a well-injected specimen, are seen to be numerous, and are frequently noticed partially, and not uncommonly completely, surrounding the individual vesicles. As mentioned, these tubes vary very much in size and form—in fact, they appear to adapt themselves accurately to the intervals left between the vesicles. This being the case, as might be expected, the diameter of a tube rarely remains constant for any distance; and where the intervals left between the vesicles are larger, the tubes expand into *lymphatic spaces* having the most irregular shape.

The lymphatic tubes, then, both large and small, together with the lymphatic spaces, form a dense rounded network of freely anastomosing canals, which permeates the entire substance of the thyroid gland. *In no case have I seen any indication of the lymphatics terminating in blind extremities*, and can only attribute such an appearance to an imperfect injection. The distinctly tubular character of the tubes, as well as the form of the spaces and tubes generally, are best seen in specimens injected with Berlin blue (figs. 2 & 3). In perfectly injected parts of silver preparations a continuous layer of endothelial cells is seen lining both larger and smaller lymphatic tubes and lymphatic spaces. Figs. 4 & 6 represent lymphatic tubes and spaces lined by the endothelium, which in some places has been accidentally cut away.

The endothelial cells are somewhat elongated, and present an irregularly sinuous outline. They form a delicate membrane, adhering closely to the outer wall of the vesicles. In a thick section this can be well seen following accurately the walls of the vesicles, and covering them, as it were, like a thin veil. (Attempts to represent this disposition of

the endothelial membrane are seen in figs. 5, *c*, & 6.) In these silver preparations a frequent appearance is that of a small artery traversing a lymphatic, and completely surrounded by a layer of endothelium, as represented in fig. 5, *b*.

Once familiar with the appearances in preparations in which the silver injection has been successful, the walls of the lymphatic tubes and spaces may be recognized between *almost all* contiguous gland-vesicles in parts where the injection has not penetrated.

They appear in this case as two fine dark wavy lines, studded at intervals with the nuclei of the endothelial cells seen in profile (figs. 13, 14, &c.). The nuclei then appear as staff-shaped bodies, and are of a much darker colour than when seen from their broad surface. The walls of the lymphatics presenting this appearance can usually be seen extending quite up to the free extremity of the inflexions mentioned above (p. 560). Where two vesicles are in apposition, it is not uncommon to see the two dark lines representing the opposite endothelial walls separated for a short distance by a small quantity of a transparent material.

It is possible that this appearance, attributed to the lymphatics, may *in some instances* be produced by capillary blood-vessels. Judging, however, from specimens in which the lymphatics are injected, it is probable that we have to do with such vessels, although it is not possible to distinguish the nucleated membrane forming the wall of a capillary blood-vessel from that of a lymphatic.

The Contents of the Lymphatics.—Before concluding this description of the lymphatics I must say a few words with regard to the contents of these vessels.

On examining the lymphatic vessels in a specimen injected with Berlin blue, and stained with picrocarminate of ammonia, by far the greater part of their cavity is seen to be filled with a granular material of a more or less bright yellow colour. The blue injection occupies the peripheral portion of the lumen of the vessel, forming bands of colouring-matter between the wall of the vessel and its contents. In fig. 1, *b* represents the granular contents of a lymphatic vessel, and the dark line surrounding this indicates the position of the injection. On examining the lymphatic tubes some of them are seen to contain this granular material; the greater part, however, in a well-injected specimen, are filled with blue injection. It is probable that the injection first entering the smaller tubes, *i. e.* the rootlets, forces their contents, or at least a part of them, onwards into the larger tubes, and from these into the lymphatic vessels. From the relation existing between the injection and the contents of the vessels, I am led to the belief that during life the contents are of a *viscid consistence*. This conclusion results from the following considerations:—If at the time of the injection the contents were fluid, or of the consistence of ordinary lymph, the injection on entering the vessels would either force the contents of the same before it or commingle with them. The injection, however, was performed *immediately* after death, before the contents could have had time to coagulate; and the injection, as we have seen, does *not* mix with the contents, but forms a separate layer between them and the wall of the vessel. It therefore follows that the contents of the lymphatic vessels must during life have been more or less viscid in character.

In sections stained with hæmatoxylin the contents of the lymphatics usually present a uniform appearance, but are sometimes finely granular. They stain of a faint greyish-violet colour.

In addition to this peculiar material, a few globules of a hyaline substance sometimes appear in the lymphatics.

II. PARENCHYMA.

Besides the stroma, lymphatics, blood-vessels, &c. between the vesicles, there is another tissue, to which, as far as I am aware, no allusion is made by authors on this subject.

To this tissue I propose to give the name of "parenchyma," on the supposition that it is possibly analogous to the parenchyma of the testis as described by KÖLLIKER, HENLE, and MICHALKOVITCH.

Characters of the Parenchyma.—On examining with a high power (as VÉRICK'S obj. 8) specimens stained with hæmatoxylin and mounted in balsam, the attention is attracted by numerous cells differing markedly in size and shape from the epithelial cells amongst which they lie.

These cells present usually a more or less rounded appearance, and are considerably larger than the adjacent epithelial cells. Their cell-substance is finely granular, and they are each provided with a single large nucleus.

It frequently happens that these cells present an irregular outline, being at the same time smaller, as if the cell-substance had shrunk up round the nucleus. When this is the case a space is left between it and the surrounding structures (*vide* figs. 8, *b*, 10, *b*, 11, *b*, 12, *b*, 14, *b*, and 15, *b*). At some parts of the specimens, however, this is not the case, and the cell-substance then presents a regular rounded outline, and is in contact with the neighbouring elements (*vide* figs. 9, *c* & 12, *c*).

The nuclei of the parenchymatous cells are round or oval in shape, and have a well-marked outline. They are larger than those of the epithelial cells, and do not stain quite so darkly with hæmatoxylin. In their interior are seen several nucleoli.

The parenchymatous cells are met with either alone (figs. 8 & 13) or in groups (figs. 9, 10, 11, 12, 14, & 15). In the latter case several (often three) frequently appear to be situate in a common cavity, which they do not fill out, as shown in figs. 10, 11, & 14. As regards the *position* occupied by these cells, and their relation to the walls of the vesicles, *four* different appearances at least are presented:—

1. The cells are situate, either singly or in groups, *external* to the vesicles, and separated from their cavity by a layer of *normal epithelial cells* (*i. e.* epithelial cells as described above at page 560). See figs. 10 & 15.

2. Other parenchymatous cells, also situate in the intervesicular spaces, are seen to be separated from the cavity of the adjoining vesicle by a layer of *flattened epithelial cells*, the latter presenting a concave surface to the parenchymatous cells. See figs. 8, 9, & 11.

3. Some parenchymatous cells are seen encroaching on the layer of epithelial cells to

such an extent that they are only separated from the cavity of the vesicle by a *thin membrane* (figs. 12, *c* & 9, *c*). They lie, as it were, in a cup formed by the flattened epithelial cells.

4. In other cases the parenchymatous cells are seen lying in a cup or hollow formed by the epithelial cells, and in which the flattened epithelial cells, or the membrane, separating the parenchymatous cells from the cavity of the vesicle have given way, thus placing the parenchymatous cells in *direct communication* with the contents of the vesicle (figs. 12, *b*, 13, *b*, & 14, *b*). In this, as in all other situations described, the parenchymatous cells may be single or several together, apparently in a common cavity.

Lastly, rounded cavities or cups, similar to those shown in figs. 12, 13, & 14, whose walls are formed by flattened epithelial cells, and which communicate freely with the vesicle, may be frequently seen in *an empty condition*.

The simple and, as it appears to me, the only reasonable interpretation of the above facts is this:—The parenchymatous cells, either in groups or singly, lie originally in the intervesicular tissue, outside the epithelial walls of the vesicles. They begin to make their way into a neighbouring vesicle by pressing on the epithelial wall of one with which they are in contact. This pressure exerted by a parenchymatous cell causes the epithelial cells to lose their quadrilateral outline, and to present a more or less triangular or crescentic appearance. The pressure continuing, the epithelial cells become flattened, and finally either separate at once (figs. 13, *b* & 14, *b*) or first become reduced to a thin membrane, which then gives way (fig. 12, *b*). In either case the result is the same. The parenchymatous cell is placed in direct communication with the contents of the vesicle, and can escape into the cavity of the same. And that it does so is shown by the fact that these cups or hollows formed by flattened epithelial cells are frequently seen in an empty condition, having lost their parenchymatous cells.

To sum up this process: it appears that *the cells forming the parenchyma of the thyroid gland of the dog originate in the intervesicular tissue external to the walls of the vesicles; from some cause (inherent movement, or growth of cells behind them) they exert pressure on the wall of an adjoining vesicle; the cells of this become flattened out or absorbed, and finally give way, allowing the parenchymatous cells to escape into the cavity, and to form a constituent of the contents, of the vesicle; but what part these cells take in the formation of the contents of the vesicles I am unable to state.*

The distribution of parenchyma through the gland appears tolerably uniform, though probably its cells are more numerous between the small than between the large vesicles.

As above mentioned, in some places they are numerous and form groups, whereas in others they appear only thinly scattered on the walls of the vesicles. As I have observed them in all thyroid glands of the dog that I have carefully examined, they must be regarded as normal and constant structures.

The parenchymatous cells can usually without difficulty be distinguished from the small vesicles, which they frequently resemble in size. The former are less highly refractive, and possess a nucleus as above described. In fig. 15 the two are seen represented side by side.

Resemblance between the contents of the Vesicles and those of the Lymphatics.—In conclusion I wish to draw attention to the close resemblance existing between the contents of the vesicles and those of the lymphatics. This resemblance will probably have already struck the reader from the description of these two substances given above (pages 560 and 562).

There are several reasons for considering that the two substances are identical:—

1. *The general Appearance and Staining with Reagents.*—In specimens prepared as above, and stained with picrocarminate of ammonia, they *both* present a granular appearance and stain of a yellow colour, more or less bright. In sections stained with hæmatoxylin they *both* present generally a uniform, sometimes a finely granular, aspect, and stain of a greyish-violet colour.

2. *The Consistence.*—The reasons for considering the contents of the lymphatics to be during life of a *viscid consistence* have already been given (see above, page 562). The contents of the vesicles are (as stated above, page 558) described by KÖLLIKER and FREY as consisting of a clear *viscid* fluid; and, as far as I have seen, there appears no reason to doubt this assertion, though I have not directly proved its accuracy.

From these facts it appears that the contents of the lymphatics are *morphologically identical* with those of the vesicles, and they give a strong reason for suspecting that the two materials are also identical in other respects.

It is of material importance to remember that in all but one or two of the cases which have been examined, most of the vesicles, as well as the lymphatics, contained the material above described; and it is further important to bear in mind that the material in the lymphatics fills and even distends the vessels completely, without containing any formed corpuscles; the material cannot therefore be lymph. Hence it is reasonable to think that one, possibly the chief, function of the thyroid gland is the formation, within the vesicles, of a material which is transferred from these by the lymphatics to the general circulation, there to serve some purpose in the animal economy as yet unknown.

The close relationship existing between the lymphatic tubes and the walls of the vesicles, together with the abundant distribution of lymphatics both within and without the thyroid gland, appear to lend support to this view.

This theory is not novel; for FREY (*op. cit.* p. 232), speaking of the glands formed of closed vesicles, says:—“The vesicles are supposed to form a secretion in their interior from the component parts of the blood, and to pass the same on, when ready, to the blood-vessels and lymphatics for removal.” He alludes to this as “a very insufficient explanation.” And he may well do so, seeing that he gives *no reason* in support of it; for neither FREY, nor any other author I have consulted, alludes to the contents of the lymphatics, still less to the *identity (morphological, at least) existing between the contents of the vesicles (where the material is supposed to be formed) and those of the lymphatics (by which it is supposed to be carried off)*; nor do they give any other ground in support of this view.

The thyroid gland being a body about whose function we know at present absolutely

nothing, any clue likely to throw some light on this subject is of value ; hence my reason for introducing the above remarks, which are, of course, still in a large degree conjectural. It will be very interesting to examine the thyroid gland in other animals, and to investigate more closely the nature of this peculiar material, subjects which I propose to pursue.

The above research was made at the suggestion, and under the direction, of Dr. KLEIN, to whom I wish to return my best thanks.

EXPLANATION OF THE PLATES.

PLATE 47.

- Fig. 1. From a transverse section of the thyroid gland, injected with Berlin blue and stained with picrocarminate of ammonia. (VÉRICK'S obj. 6, oc. I.)
- a.* Lumen of an artery, seen in transverse section.
 - b.* Cross section of a large lymphatic vessel that surrounds it. This is seen filled with a granular material, stained yellow in the specimen. The dark outline indicates the position occupied by the Berlin-blue injection.
 - c.* Contents of the vesicles, which present a similar appearance to *b.*
 - d.* Walls of gland-vesicles, the epithelial cells of which are flattened by the action of the reagents.
- Fig. 2. Small lymphatic tubes and spaces injected with Berlin blue, from a longitudinal section of the thyroid gland. Hardened in MÜLLER'S fluid and alcohol. (Obj. 6, oc. I.)
- Fig. 3. A more general view of the lymphatic tubes and spaces, from a similar specimen. In this preparation the tubes appear somewhat shrunk by the action of the reagents. (Obj. 2, oc. I. Tube drawn out.)
- Fig. 4. Lymphatic tubes showing endothelium, from a transverse section of the gland injected with nitrate of silver. In this specimen, which is rather thick, the tubes, which in the drawing appear on one level, are situated on various planes, and frequently dip down among the vesicles. (Obj. 3, oc. III.)
- Fig. 5. From a transverse section of the thyroid gland injected with nitrate of silver.
- a.* Interior of a large lymphatic cut across.
- Running across its cavity is seen an artery (*b*) which is surrounded by the endothelial wall of the lymphatic. This endothelial layer is also seen investing the outer surface of the neighbouring vesicles. The structure of these is only represented at one part (*c*). (Obj. 3, oc. III.)

PLATE 48.

- Fig. 6. From a transverse section injected with silver, showing lymphatic tubes surrounding a group of vesicles and giving off smaller branches. The endothelial

membrane, which in some places is cut away, is seen investing the outer surface of the vesicles. The structure of the vesicles is not represented, their outlines being indicated by the shading. (Obj. 3, oc. III.)

Fig. 7. From a longitudinal section of the gland injected with silver, showing the wall of a lymphatic vessel. The endothelial cells are seen with their oval-shaped nuclei faintly stained with hæmatoxylin. Some of the cells have two, others three nuclei. Some of the nuclei are seen crossed by the silver lines. (Obj. 3, oc. I.)

Figs. 8 to 15 illustrate the appearances presented by the "parenchymatous" cells of the thyroid gland. They are all taken from sections of the gland hardened in alcohol and stained with hæmatoxylin. All except fig. 11 are drawn with obj. 8, oc. I.

In figs. 8, 10, 11, 12, 13, 14 and 15, *a* indicates the interior of a vesicle, and *b* the parenchymatous cells.

Fig. 8. From a transverse section, representing a small portion of the wall of a vesicle (*a*) with its layer of epithelial cells. A large round parenchymatous cell (*b*) is seen, which has so flattened out two epithelial cells that it has formed on their outer aspect a cup, in which it lies.

Fig. 9. From a longitudinal section, showing several parenchymatous cells (with their cell-substance not shrunk) situate at various distances from the interior of the vesicles (*aa*). Some are separated from the cavity of the vesicle by merely a membrane (*c*), others by flattened epithelial cells, and others, again, by normal epithelial cells. Between *a* and *a* a cavity is seen left between the epithelial cells, out of which a parenchymatous cell has probably escaped.

Fig. 10. From a transverse section. Three parenchymatous cells (*b*) with their nuclei are seen apparently situate in a common cavity, and not encroaching, as far as can be seen, on the wall of a vesicle. Their cell-substance appears shrunk.

Fig. 11. From a transverse section, showing a similar space containing apparently two parenchymatous cells (*b*), one of which presents the appearance of hanging into the space and of being attached to the epithelial cells. (Drawn with obj. 8, oc. III.)

Fig. 12. From a transverse section. A portion of the epithelial wall (*a*) of a vesicle is seen in which are two parenchymatous cells (*b, c*). The one (*c*) with its cell-substance not shrunk is apparently still separated from the cavity of the vesicle by a membrane; the other (*b*) exhibits a shrunken cell-substance, which, together with its nucleus, stands in free communication with the cavity of the vesicle (*a*).

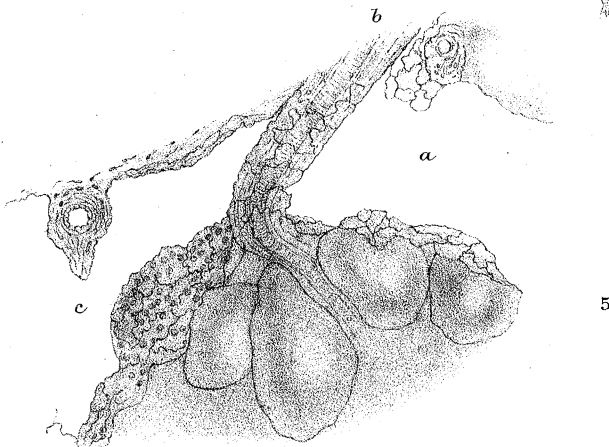
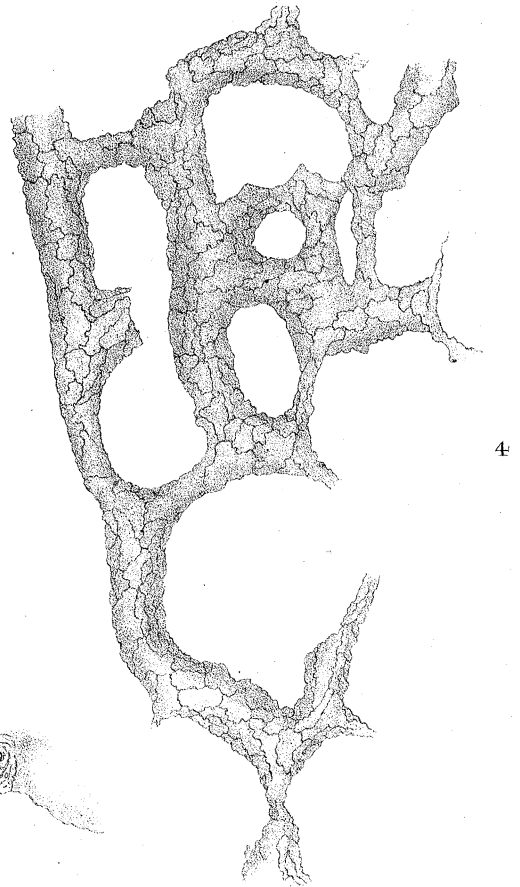
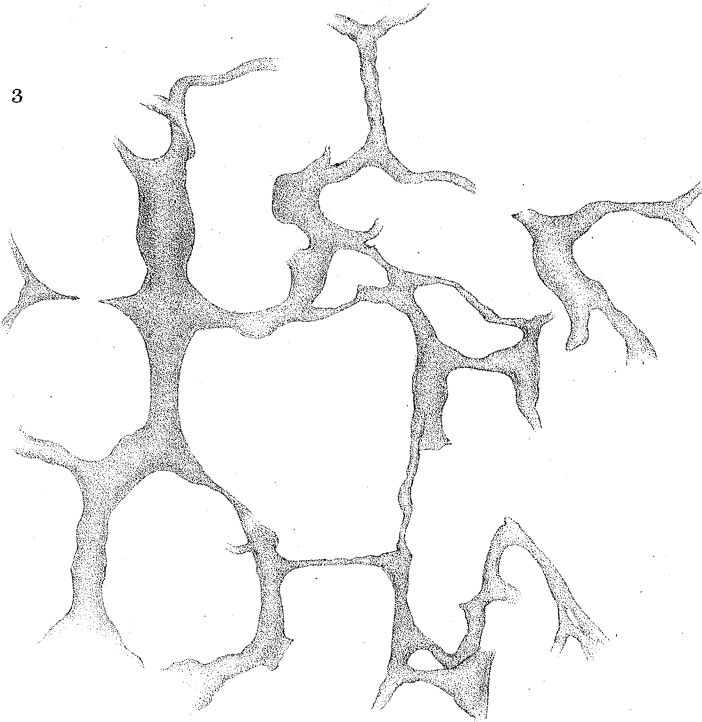
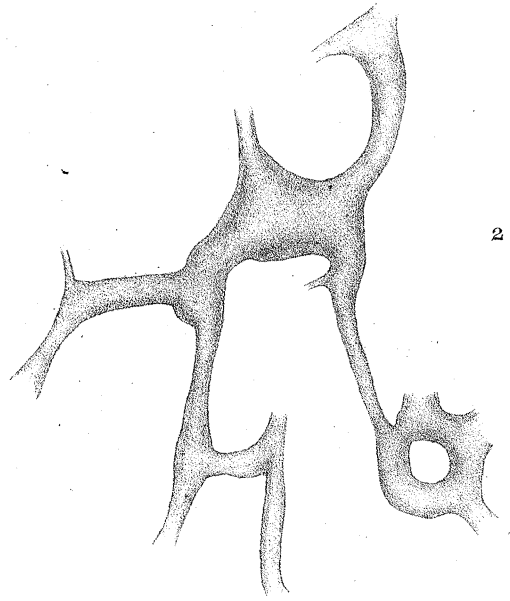
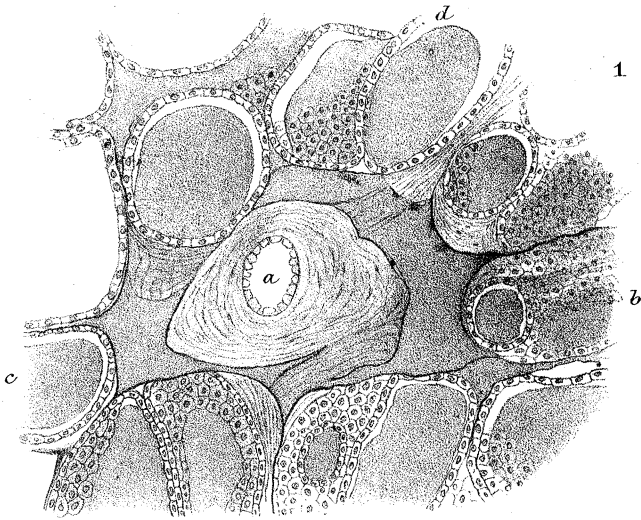
Fig. 13. From a longitudinal section of the gland, showing a portion of the walls of three contiguous vesicles (*aaa*). In the wall of one is seen a parenchymatous cell (*b*), with its cell-substance slightly shrunk, which, owing to the flattened epithelial cells surrounding it having separated, stands in direct communication with the interior of the vesicle (*a*). This figure shows well the walls of

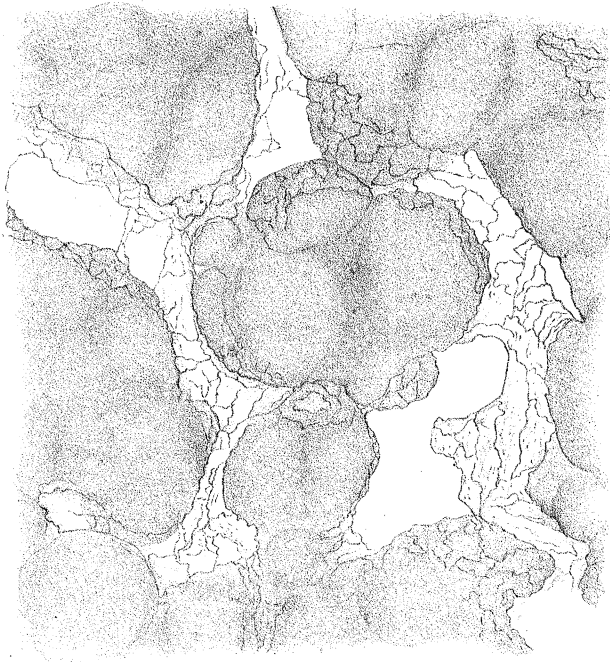
the lymphatics, together with the nuclei of their endothelial cells seen in profile (see above, page 562).

Figs. 12 & 13 represent a further stage in the movement of the parenchymatous cells to that seen in figs. 8 and 9.

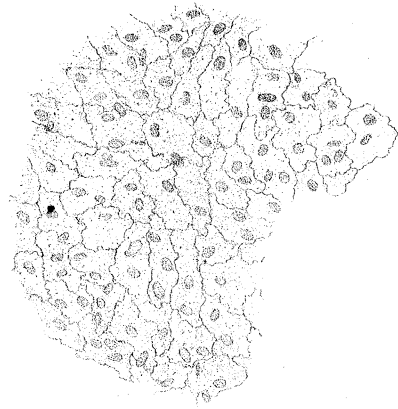
Fig. 14. From a longitudinal section, showing three parenchymatous cells (*b*), apparently situate in a common cavity. The wall of a neighbouring vesicle has become flattened out, and the flattened epithelial cells have separated, placing the parenchymatous cells in free communication with the interior of the vesicle (*a*).

Fig. 15. From a transverse section, showing parenchymatous cells (*b*) and also small vesicles (*c*). The latter with opaque uniform contents, as above described (p. 560); the former exhibiting a granular cell-substance and large oval-shaped nuclei. The cells separating them, possibly from being shrunk, present almost the appearance of a reticulum.

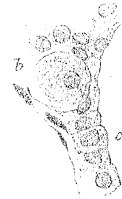



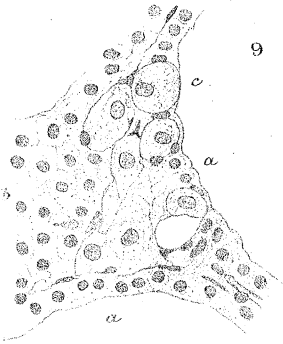
6



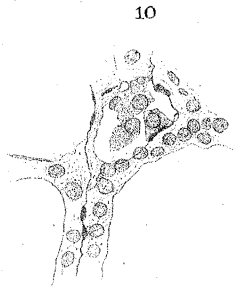
7



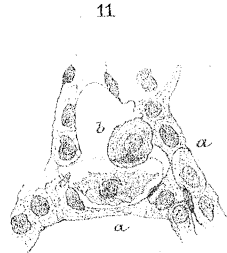
8



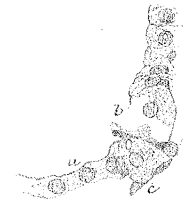9



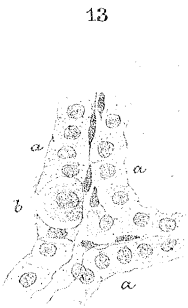
10



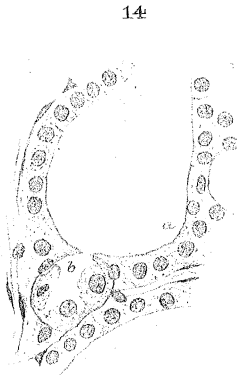
11



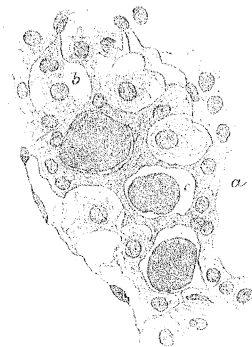12



13



14



15